

Comparative study of heart of vertebrates

Circulatory System in chordates:

The blood vascular system is the major type of circulatory system in chordates. It is specifically of closed type i.e. blood flows through the capillaries connected by two major vessels called arteries and veins. The heart, one of the most important components of this system, is a modified blood vessel with a thick muscular wall. It contracts periodically to pump the blood thereby acting as a pumping machine.

Types of circulation through heart in chordates:

In chordates, there are two types of circulation through the heart.

- a. **Single circuit:** In this type of circulation, only deoxygenated blood from different body parts enter the heart through veins. The heart pumps this deoxygenated blood to the gill for aeration. Oxygenated blood from the gills becomes distributed throughout the body. This type of heart is called a venous heart. Eg. Heart of fishes.

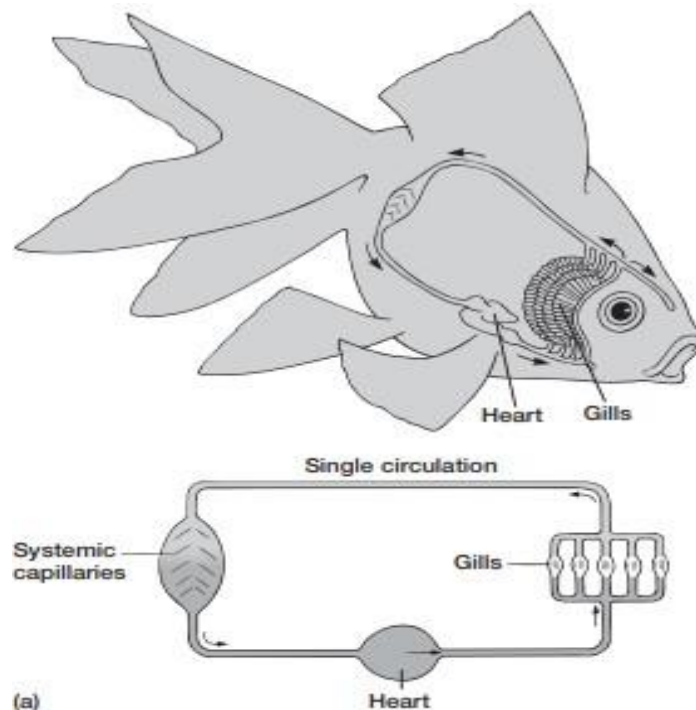


Figure 8: Single circuit circulation in fish heart.

b. Double circuit: In this type of circulation, deoxygenated blood from different body parts enters the right part of the heart through veins. The heart pumps this deoxygenated blood to the lungs for aeration. Oxygenated blood from the lungs is pumped again by the left part of the heart to supply to the different body parts. This type of heart is called a pulmonary heart. Eg. Heart of amniotes.

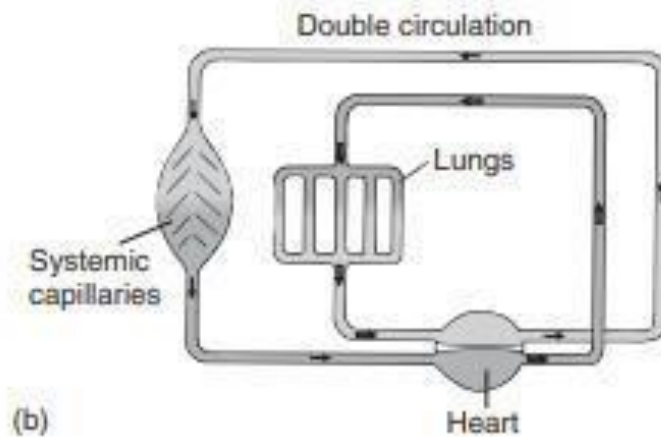
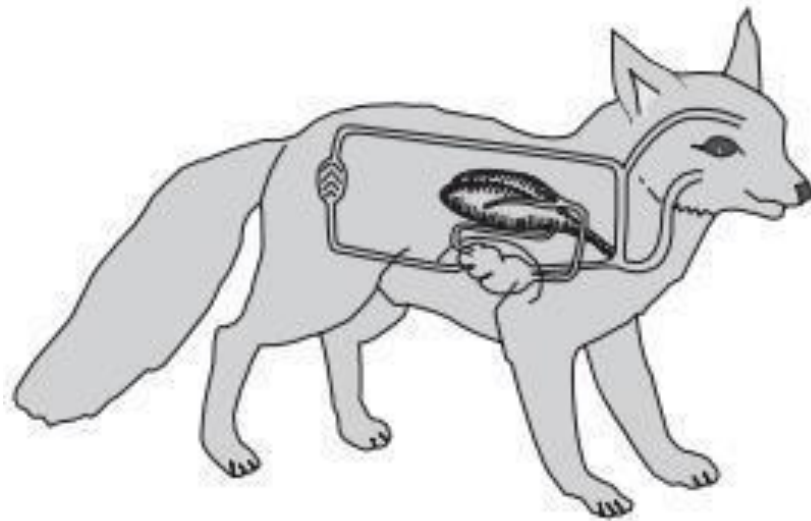


Figure 9: Double circuit circulation in amniotes heart.

Evolution of heart in vertebrates:

A. Primitive vertebrates:

In primitive vertebrates like Cephalochordate *Branchiostoma*, a true heart is absent. The function of blood pumping is performed by a muscular and contractile part of the ventral aorta.

As this type of heart is not divided into chambers, some zoologists consider it as a singlechambered heart.

B. Cyclostomes:

The existence of a true heart starts from cyclostomes like *Petromyzon*, *Myxine*, etc. In these animals, heart is of simplest structure consisting of four chambers named as sinus venosus, auricle, ventricle and conus arteriosus. Blood is received by the sinus venosus part and then flows through the auricle, ventricle and conus arteriosus in a linear series. **C.**

Superclass Pisces:

The fish heart is enclosed in a pericardial cavity, unlike cyclostomes. Conus arteriosus becomes continuous with the ventral aorta in front of this cavity.

C.1. Elasmobranch: In elasmobranchs like *Scoliodon*, the heart consists of four chambers just like cyclostomes among which two chambers are regarded as main chambers (auricle and ventricle) and other two are accessory chambers (sinus venosus and conus arteriosus). Sinus venosus receives deoxygenated blood from other veins and sends this blood to the auricle through sinoatrial aperture which generally remains guarded by two valves. From the auricle, blood is directed into the ventricle by atrioventricular aperture, again guarded by two valves. The muscular ventricle opens into a comparatively narrow tube conus arteriosus. In between the ventricle and conus arteriosus, a series of semilunar valves are present. All the valves function in preventing the backflow of blood (Figure 10, 11)

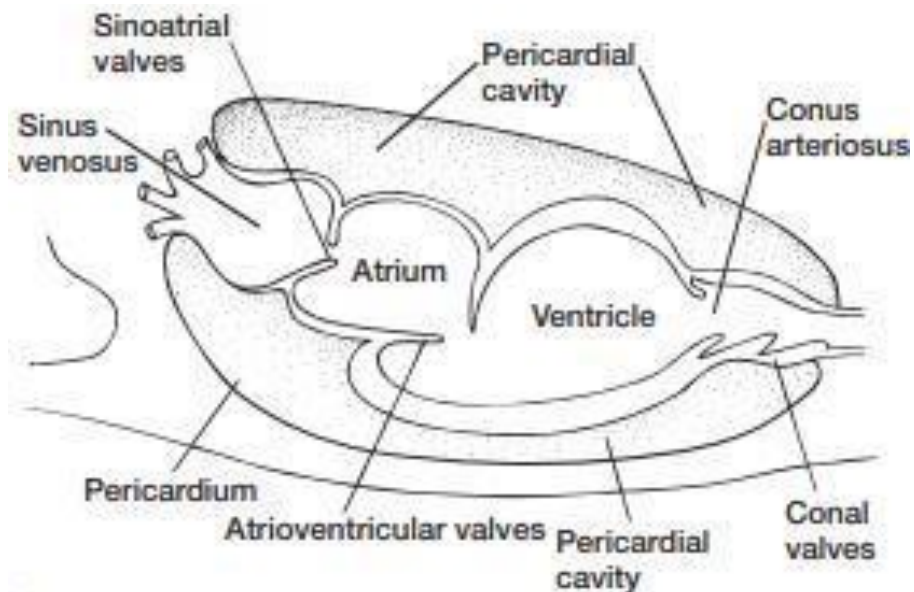


Figure 10. Basic heart structure in fishes.

C.2. Teleost: the heart of bony fishes is structurally almost the same as that of the elasmobranchs. The only difference lies in the structural modification of the conus arteriosus. In most teleostei, part of the ventral aorta near the conus arteriosus becomes enlarged to form a muscular and elastic structure named as bulbus arteriosus (Figure 11).

Table 2: Modifications of conus arteriosus in bony fishes

Name/class of bony fish	Modification in conus arteriosus structure	Modification in number of semilunar valves
<i>Polypterus, Lepidosteus</i>	longer	numerous
<i>Amia</i>	reduced	fewer
Most teleostei	Reduced or absent, fuses with ventricle	Single pair

Polypterus, Lepidosteus longer numerous

Amia reduced fewer

Most teleostei Reduced or absent, fuses with ventricle

In fishes, a two-chambered heart pumps only the venous blood (*not arterial one*) to send it towards the gills for oxygenation. Thus, this type of heart is called a venous or branchial heart.

C.3. Dipnoi: Due to the development of lungs or air bladder, the structure of heart is further modified in dipnoans to support the terrestrial mode of respiration. The auricle is divided into two chambers (right and left auricle) by an incomplete inter-auricular septum perforated by foramen ovale. Due to this incomplete partitioning and presence of foramen

ovale, the oxygenated blood received in the left auricle from pulmonary veins and the deoxygenated blood received in the right auricle through sinus venosus get mixed easily. Further existence of a partial inter-ventricular septum in the ventricle and a horizontal septum in the conus arteriosus show the advancement in heart structure over elasmobranchs and teleosts. Therefore, dipnoan heart can be regarded as a three-chambered transitional heart (Figure 11).

D. Class Amphibia:

D.1. Urodeles: Being a tailed aquatic amphibian group, the urodele heart is partially threechambered due to the presence of an incomplete inter-auricular septum like dipnoans. However, an incomplete inter-ventricular septum is absent in urodele heart.

The left auricle receives aerated blood through the pulmonary veins and the right auricle receives deoxygenated blood from the sinus venosus. An incomplete inter-auricular septum allows the mixing of oxygenated and deoxygenated blood. Another important structural modification is replacement of conus arteriosus by bulbus arteriosus (Figure 11).

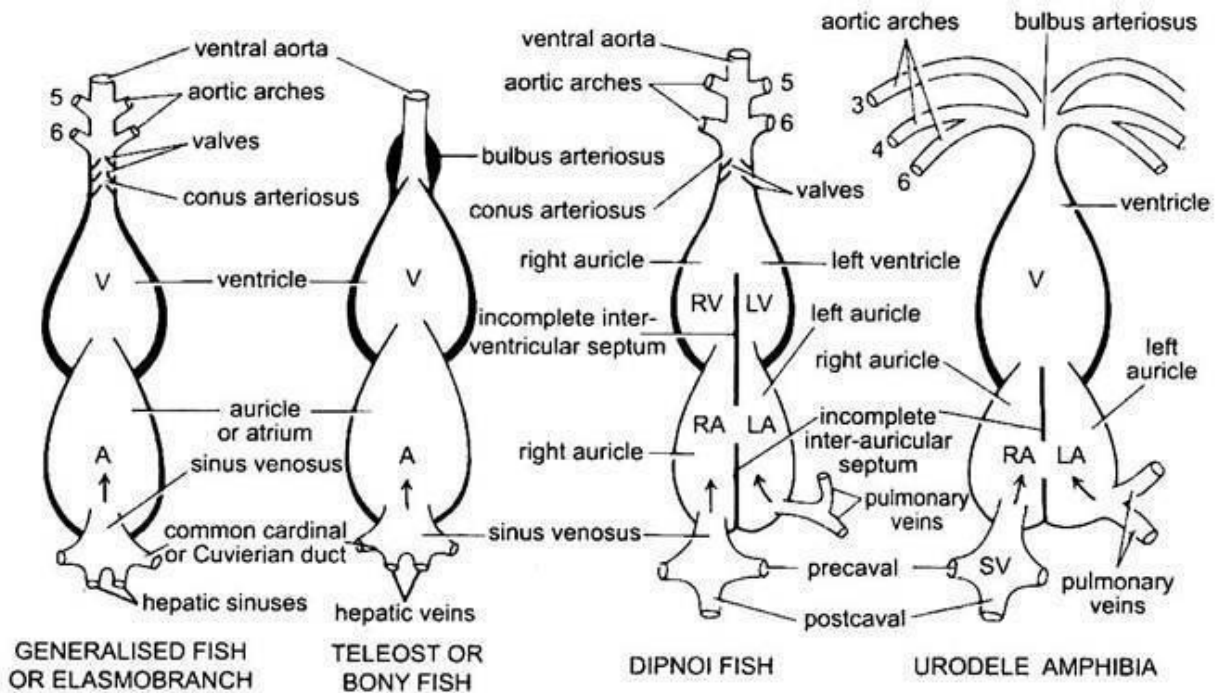


Figure 11: Structural modifications of heart in aquatic vertebrates (fishes and urodele amphibians) (Kotpal, 2010-11)

D.2. Anurans: The heart in anuran amphibians exhibit some advancements over the piscine heart due to their adaptation to the terrestrial mode of life. Sinus venosus and atrium

are placed dorsally. The inter-auricular septum is complete and divides the auricle into left and right auricles. Due to the absence of foramen ovale in inter-auricular septum, the mixing of oxygenated and deoxygenated blood does not occur in this type of heart. Although the interventricular septum is not formed within the ventricle, the muscular ventricular wall and presence of ventricular trabeculae allow little mixing of oxygenated and deoxygenated blood. Further, conus arteriosus contains an S-shaped spiral valve, dividing the lumen of this narrow tube into two chambers – cavum aorticum and cavum pulmocutaneum. The presence of spiral valve allows the conus arteriosus to direct the oxygenated and deoxygenated blood into the systemic and pulmonary vessels respectively (Figure 12). **E. Class Reptilia:**

Presence of strong muscles in the cardiac wall is a further advancement in reptilian heart over that of the amphibians.

E.1. Squamatan reptiles: In squamatan reptiles, conus arteriosus and ventral aorta split into three distinct trunks – one pulmonary and two systemic (right and left). Mixing of oxygenated and deoxygenated blood in the heart may occur in three ways – i. an incomplete inter-ventricular septum partially divides the ventricle into right and left ventricles, therefore allowing the mixing of deoxygenated and oxygenated blood to a certain extent. ii. Dorsal aorta is formed by the joining of right and left systemic aortae (carrying deoxygenated and oxygenated bloods respectively) in which mixed blood flows. iii. Foramen of panizza, an opening, connecting two aortae at their bases, allows the mixing of arterial and venous blood (Figure 12).

E.2. Crocodilian reptiles: Interestingly, crocodiles show further advancement in heart structure over that of squamatan. Mixing of oxygenated and deoxygenated blood does not occur due to the presence of complete inter-ventricular septum and obliteration of foramen of panizza. Therefore, a crocodilian heart is completely four-chambered (Figure 12).

F. Class Aves and Mammalia:

Birds and mammals possess the same modifications in their heart structure. Due to the presence of a complete interventricular septum, their heart is truly four-chambered. The right auricle receives venous blood via two precaval and two postcaval veins as the sinus

venous becomes completely incorporated into the right auricle. Venous blood from the right auricle is pumped to the lungs for aeration through the right part of the heart while the left part of the heart pumps the oxygenated blood into the systemic circulation after receiving it in the left auricle from the lungs via pulmonary veins. The circulation of venous and arterial blood through the right and left halves of heart respectively is called double circulation which is a salient feature of blood vascular system in birds and mammals. As the inter-ventricular septum is complete, there is no mixing of arterial and venous blood in this type of heart and for which this type of heart is called pulmonary heart. In addition, the coronary sinus collects the blood from cardiac wall and pours it into the right auricle. Unlike reptiles, conus arteriosus is replaced by two aortae – a pulmonary aorta (from the right ventricle to the lungs) and a systemic one (from the left ventricle to various body parts). A depression named as fossa ovalis in inter-auricular septum of the adult heart marks the site of foramen ovale (Figure 12).

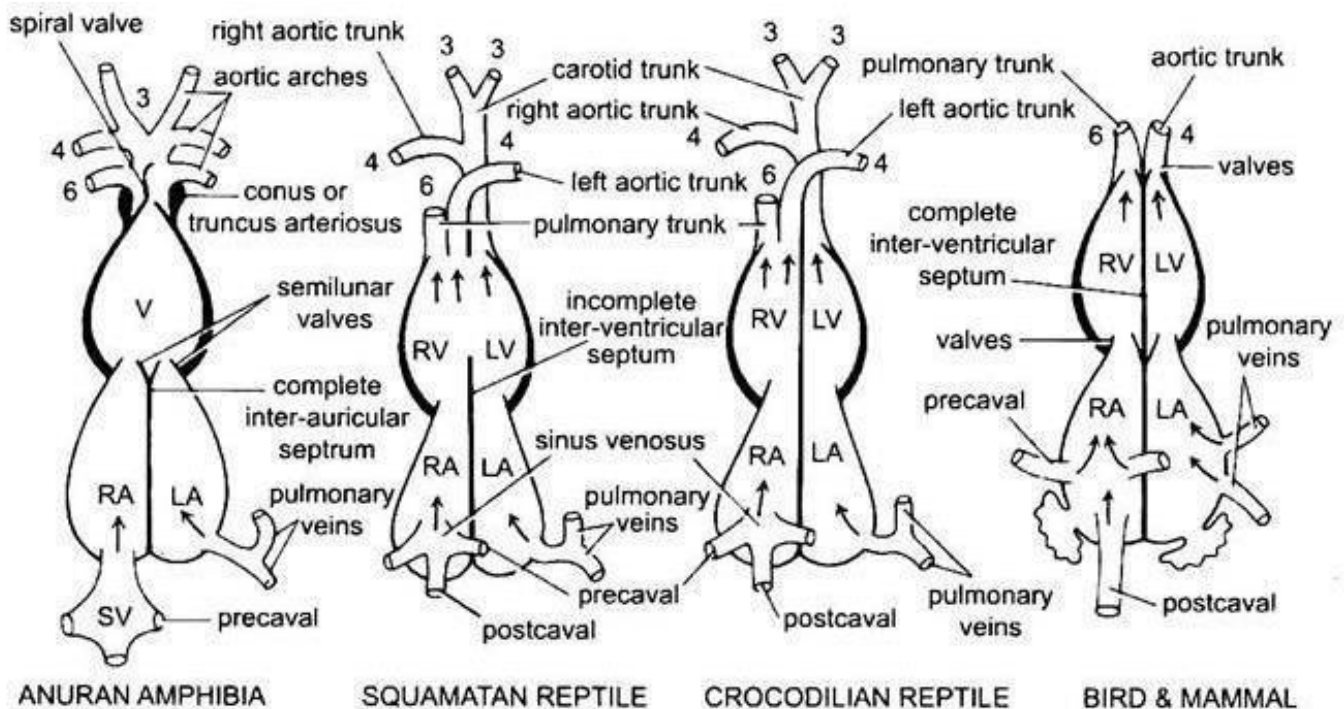


Figure 12: Structural modifications of heart in terrestrial vertebrates (anuran amphibians, reptiles, birds and mammals) (Kotpal, 2010-11)

Table 3: Comparative account of heart in lower and higher vertebrates

Sinus venosus	Present	Present	Present	Present	Present	Incorporated into right auricle	Incorporated into right auricle
Auricle	1 chambered	1 chambered	Partially 2 chambered	2 chambered	2 chambered	2 chambered	2 chambered
Inter-auricular septum	Absent	Absent	Incomplete	Complete	Complete	Complete	Complete
Ventricle	1 chambered	1 chambered	1 chambered	1 chambered	Partially 2 chambered	2 chambered	2 chambered
Interventricular septum	Absent	Absent	Absent	Absent	Incomplete	Complete	Complete
Conus arteriosus	Present	Absent	Absent	Present; spiral valve present	Present; splits into 1 pulmonary and 2 systemic trunks	Absent; replaced by a pulmonary and a systemic aorta	Absent; replaced by a pulmonary and a systemic aorta
Bulbus arteriosus	Absent	Present	Present	Absent	Absent	Absent	Absent
Mixing of oxygenated and deoxygenated blood	Does not occur	Does not occur	Occurs	Little mixing	Occurs	Does not occur	Does not occur

Table 4: Types of heart in lower and higher vertebrates

Type	Consist of	Present in
Two-chambered venous heart	1 auricle, 1 ventricle	Fishes
Three-chambered transitional heart	2 auricles with incomplete/complete interauricular septum, 1 ventricle with incomplete inter-ventricular septum	Lungfishes and amphibians
Partially four-chambered transitional heart	2 auricles, 2 ventricles with incomplete inter-ventricular septum	Most reptiles
Four-chambered pulmonary heart	2 auricles, 2 ventricles	Birds and mammals

-----XXXXX-----